

FUSIONS

VOLUME 3 NUMBER 1

MARCH 1991

Back and Forth

Physician Develops a Procedure For Using SpF®-2T Stimulator in Anterior Lumbar Interbody Fusions

Dr. Allen J. Meril, a clinical instructor in orthopedics at Southwestern Medical School (Dallas, Texas), has developed a procedure for using the implantable SpF-2T spinal fusion stimulator in anterior lumbar interbody fusions (ALIFs). *Fusions* recently interviewed Dr. Meril about his technique.

Question: Why did you develop this procedure?

Dr. Meril: The SpF stimulator has proven its ability to increase fusion rates in bilateral

lateral fusions. But 98% of my spinal fusions are interbody fusions, so I needed to develop a technique for implanting the SpF stimulator in patients requiring the extra enhancement it provides.

Question: Why do you prefer interbody fusions to other techniques?

Dr. Meril: Two reasons. First, because it is the most biomechanically sound technique. Second, because it is indicated for disc disease including disc disruption syndrome and disc instability with sclerosis, narrowing, and traction spurring.

Disc disruption or instability is painful because of the mechanical failure and possibly the abnormal biochemistry of the

(continued on page 4)

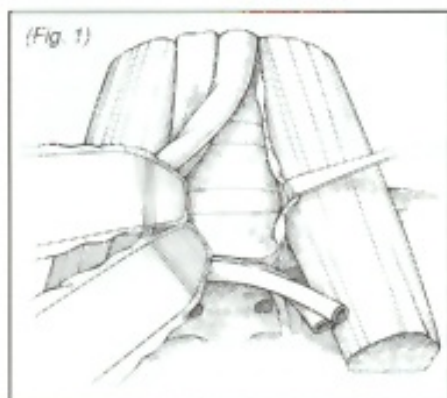


Dr. Allen Meril

Spinal Column

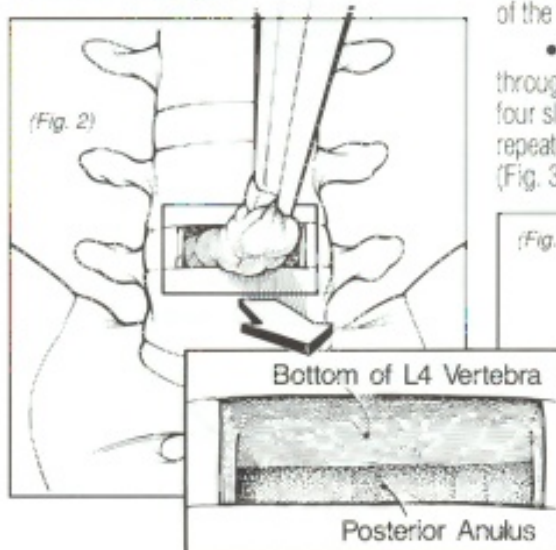
Dr. Meril's SpF®-2T ALIF Procedure at a Glance

- A transverse incision is made from the umbilicus to the iliac crest to gain exposure to the area (Fig. 1).



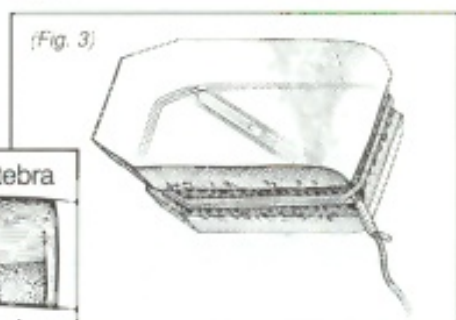
- The correct disc space is identified with insertion of a needle and radiographic verification.

- A thorough discectomy is performed. Sufficient bone is removed to create a cancellous bed (Fig. 2).



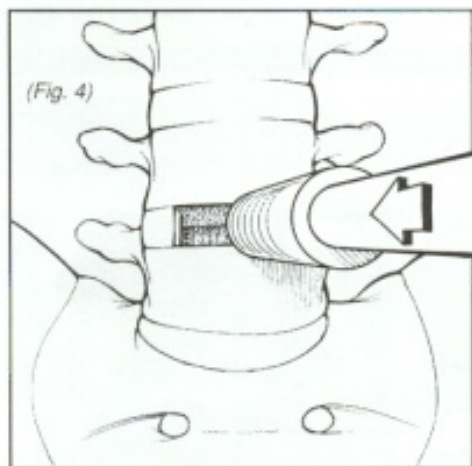
- Allograft is cut to the appropriate length. A diagonal hole and four shallow troughs are cut in the allograft for placement of the SpF-2T cathode.

- The SpF-2T cathode is passed through the diagonal hole and secured in the four shallow troughs. This procedure is then repeated with a second piece of bone graft (Fig. 3).

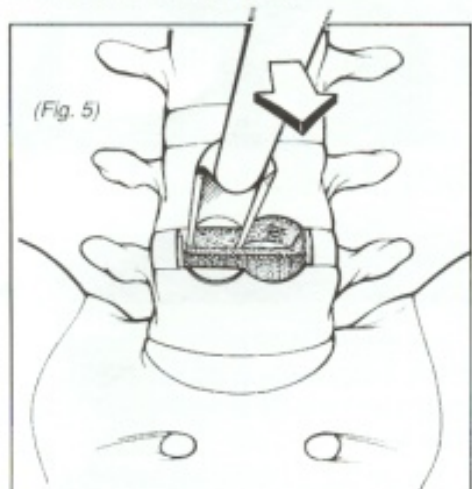


(continued on page 2)

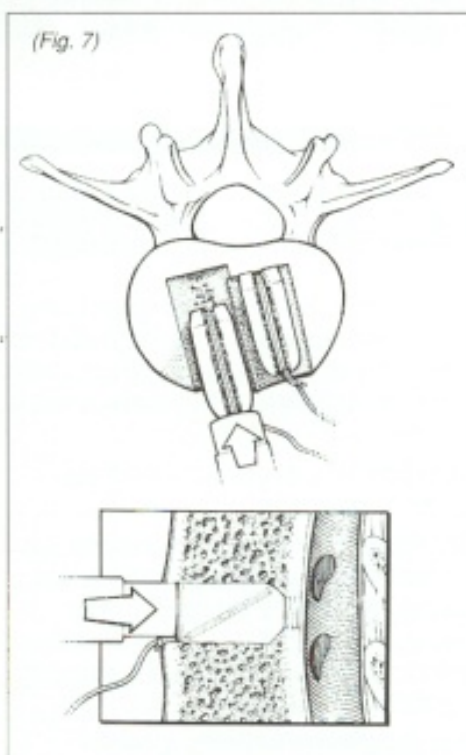
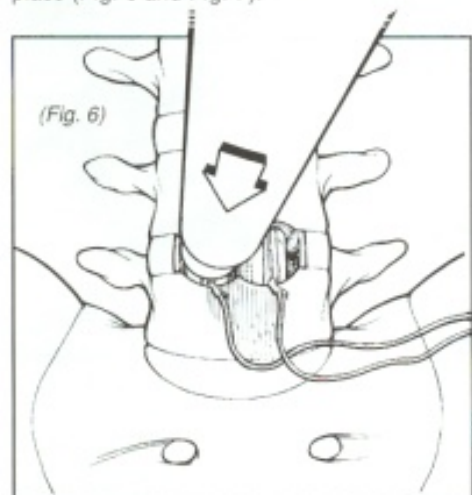
- Using a starter tool, a shallow circular cut is made (Fig. 4).



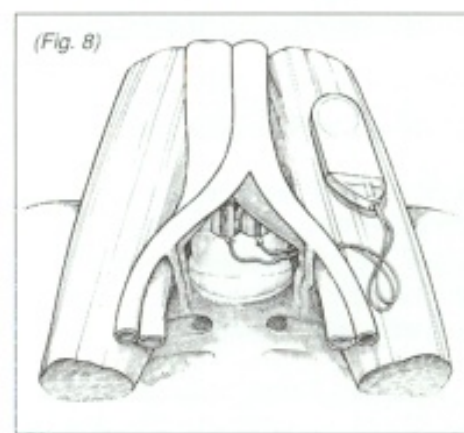
- Two circular holes are created in the intervertebral space utilizing a circular cutter on a motorized drill (Fig. 5).



- The prepared grafts are placed into the intervertebral space and tamped into place (Fig. 6 and Fig. 7).



- The SpF-2T generator is placed on the psoas muscle and the wound is closed in the ordinary fashion (Fig. 8). ■



Answers, Answers, Answers

Q Can an MRI be done if a patient has an SpF stimulator implanted?

A Based on experience over the past ten years plus testing of the implantable stimulator in an MRI environment, it appears that MRI imaging may be safely done. The implanted device should be no closer than 8" from the imaging target to insure no distortion of the MRI image. MRI does not affect device functioning or safety. We will continue to test the implantable stimulators in new MRI systems as appropriate.

Q Can an SpF stimulator be implanted in a patient who has a pacemaker?

A Yes! The SpF stimulator may be implanted in a patient with a pacemaker. The stimulator will not affect the pacemaker functioning.

Q What is the shelf life and the implant life of the SpF-T stimulator?

A The SpF-T stimulator has a shelf life of 24 months and 24 week implant life.

Q Are the SpF stimulators available in a non-detachable lead configuration?

A All SpF stimulators are now available with a fused non-detachable lead cathode configuration. These devices are available in a two or four lead configuration and either the SpF or SpF-T.

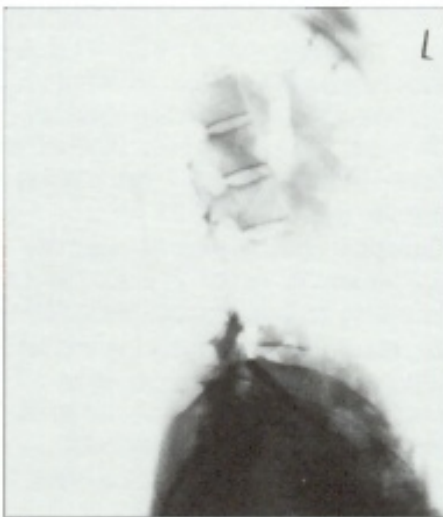Q Is there some way to position the generator in the soft tissue so it doesn't migrate?

A On the silastic head of the SpF-T generator is a suture marker that is used by surgeons to anchor the generator so it doesn't move after it is implanted. ■

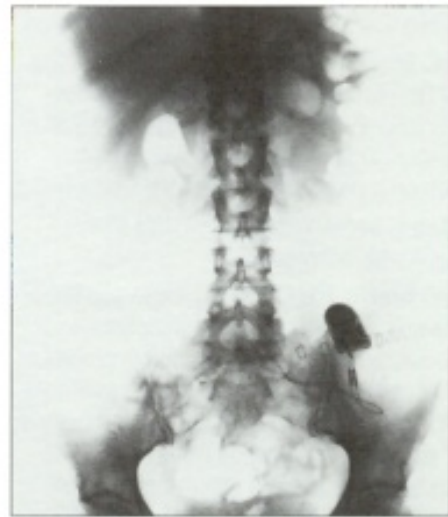
Getting Down to Cases

CASE 1

A 55 year old female sustained a low back injury in June of 1988 while working in an automotive plant. She was lifting a heavy object and experienced a sudden onset of midline low back pain radiating to her left side. A CT scan revealed a mild central bulge at L5-S1. The patient underwent a percutaneous suction diskectomy. Her pain was relieved for 5-6 weeks and then returned. An MRI showed deterioration and loss of signal intensity both in L4-L5 and L5-S1 and a central protrusion or herniation at L5-S1. The patient's discogram was positive with pain reproduction at L5-S1. In April 1990, the patient underwent an anterior lumbar interbody fusion at L5-S1, with implantation of an SpF-2T Stimulator. Tomograms taken in September 1990 show early progression of the fusion. ■



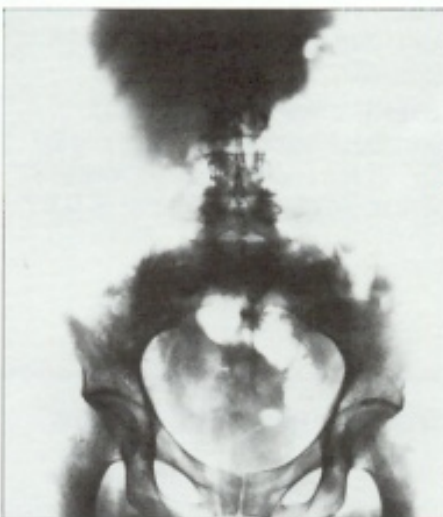
Pre-operative.



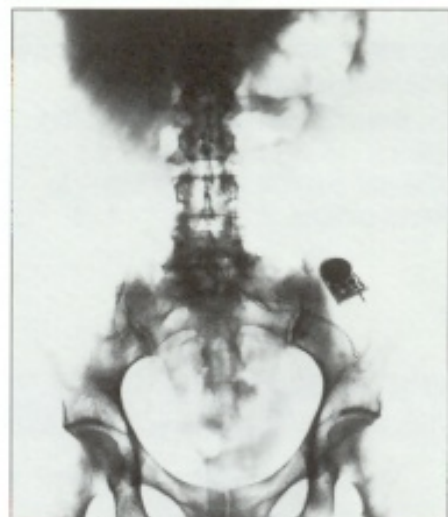
5 months after the SpF-2T stimulator was implanted.

CASE 2

A 45-year-old female with scleroderma was referred to the surgeon for evaluation of persistent low back and leg pain. She reported that she sustained an L5 fracture in 1983. A CT scan in 1987 revealed a bulging disc at L5-S1. From 1983 to 1990 she was seen and treated by several physicians without improvement of her symptoms. An MRI done in February 1990 revealed mild annular deformities at L4-L5 and L5-S1 and a decreased signal. The patient was treated conservatively without relief of her symptoms. A discogram done in August 1990 was positive at L5-S1 for pain reproduction. In September 1990, the patient underwent an anterior lumbar interbody fusion at L5-S1 with implantation of an SpF-2T Stimulator. The patient did well postoperatively and in October 1990 was started in a back rehabilitation program. A CT scan done in January 1991 shows a 90% incorporation of the graft. ■



Pre-operative - narrowing L5-S1 disc space.



3 months after the SpF-2T stimulator implanted, 90% graft incorporation.

Back Support

Allen J. Meril, MD, FAAOS, FACS, Clinical Instructor of Orthopedics at the Southwestern Medical School in Dallas, Texas, completed a 13-minute videotape demonstrating the procedure for implantation of the SpF-2T Stimulator in an Anterior Lumbar Interbody Fusion. This video is now available, along with the following four spine fusion technique videos:

- Bilateral Lateral Lumbar Fusion with Pedicle Screw Instrumentation and the SpF-2 Stimulator.
- Facet Fusion with the SpF-4 Stimulator.
- Pseudarthrosis Repair and Bilateral Lateral Lumbar Fusion with Implantation of the SpF-2 Stimulator.
- Implantation of an SpF-2T Stimulator in Posterior Lumbar Interbody Fusion.

For information on how you can obtain these videos, contact Mary Ellen Coleman toll free at 1-800-526-2579. ■

disc itself; when you remove the disc and replace it with bone graft, a large majority of patients will get better.

Question: Please describe your procedure.

Dr. Meril: Our technique is similar to that of Dr. Henry V. Crock, with two modifications. One is that we use allograft instead of autograft; the second is that we use an Anspach end cutter instead of a Crock cutter.

Question: Why did you choose this particular technique?

Dr. Meril: The Crock technique seemed to be well instrumented. Its principles are sound, and it's a relatively simple procedure that can be easily duplicated case after case. We use allograft instead of autograft because it eliminated the need to make an incision for graft removal and reduces pain at the graft site. And we prefer the Anspach cutter because it's more suitable than the Crock cutter. The only part of the instrument that turns is within the disc space, so it cannot injure adjacent structures.

Question: What is the rationale for using a solid dowel of graft?

Dr. Meril: For mechanical stability. This fusion is a load-bearing structure; the solid graft gives the structure integrity to prevent collapse.

Question: What are the risks involved in this procedure?

Dr. Meril: The major risk is vascular injury. There is also risk of injury to the ureter and dura. The implantation of the SpF-2T device adds no real additional risk. There is a small increase in the risk of infection caused by the presence of a foreign body. However, we haven't had a single case of deep infection after doing 94 ALIFs with the SpF-2T.

Question: Based on these 94 cases, can you say whether the SpF-2T is successful in increasing the fusion success rate in ALIFs?

Dr. Meril: Our study is ongoing, and the results have not been tabulated, so we cannot say for sure. However based on my review of these cases, I can say that it appears our fusion success rate is higher with the SpF-2T than without it.

In patients who did not have stimulation, a significant number – 20% to 40% – did not fuse. I am reasonably confident that the results with the SpF-2T stimulator will be better than results achieved without the stimulator.

Question: Your procedure manual describes a technique for implanting the SpF-2T in a single-level ALIF. What procedure would you use for a two-level ALIF?

Dr. Meril: The exact same procedure outlined in the manual can be used for both single- and two-level ALIFs. The only change is that when we perform a two-level interbody fusion we create a more unstable situation, which causes the patient to have considerable early postoperative pain from the surgery. Our solution is to perform segmental internal fixation. This is done primarily to reduce early postoperative pain.

Question: How much time does implanting the SpF-2T device add to the operative procedure?

Dr. Meril: Our manual recommends that the surgeon perform our procedure with the aid of two competent assistants. If this is done, implanting the SpF-2T takes no extra time, since one assistant can be preparing the graft while the other assistant and I prepare the bed. Without an assistant to prepare the graft, implanting the SpF-2T can add up to 30 minutes to the entire procedure.

Question: Where is the generator placed?

Dr. Meril: In our procedure, the generator is placed on the psoas muscle, and has caused no patient discomfort. ■

Back to the Future

The next issue of *Fusions* will feature an interview with three spine surgeons who will be discussing their use of pedicle screw instrumentation and the SpF stimulator in spine fusions. ■

INDICATION FOR USAGE

The SpF Implantable Bone Growth Stimulators are indicated as a spinal fusion adjunct to increase the probability of fusion success.

CONTRAINDICATIONS, ADVERSE EFFECTS, AND WARNINGS

There are no known contraindications, adverse effects or warnings relating to the use of this device.

PRECAUTIONS

Certain precautions should be taken in handling and in surgical placement of the generator and cathodes, and certain precautions apply when using the device concomitantly with electrosurgery, diathermy, and internal fixation.

For full prescribing information, clinical data, or to speak directly with an EBI Representative, call 1-800-526-2579.

EBI Medical
Systems

Enhancing Bone Healing
through Applied Science